

THE GOVERNING COUNCIL OF THE CAT FANCY

4-6 Penel Orliou

Bridgwater

Somerset TA6 3PG

Tel:(01278) 427575



**GUIDE TO
THE DEFECTS LISTED
IN THE GCCF
STANDARD OF POINTS**

New Edition **NOVEMBER 2003**

THE LIST OF DEFECTS IN THE STANDARD OF POINTS

When breeding to modify the shape of any species of animal to produce distinct breed types there is a danger that selection for exaggerated type will lead to deformities .

Many members of the Cat Fancy became concerned that the type of some cats was becoming too exaggerated, to the detriment of their health. Some problems had existed for many years and were becoming all too common, whilst other deformities were just beginning to be seen. In March 1985 the GCCF Veterinary Sub-Committee discussed the problem and their proposals were considered and passed by Council in June 1985.

When the Standards of Points book was reprinted in February 1986 it was prefaced for the first time by a list of defects common to all breeds. This list included not only the defects which could lead to health problems and monorchidism and cryptorchidism which already debarred adult males from competition, but squints and kinks which were already listed as defects in the majority of breeds. The preface has been reviewed by the GCCF Veterinary Sub-Committee and Executive Committee several times since then and several slight amendments have been made.

The preface as it appears in the 2003 Standard of Points reads as follows:

STANDARD LIST OF WITHHOLDING FAULTS - ALL BREEDS

Size and Condition - Withhold certificates or first prizes in kitten open classes on any exhibit which, in the opinion of the judge, is not in excellent physical condition or is undersized for its age and breed.

The following list of defects applies to ALL BREEDS.

Withhold certificates or first prizes in kitten open classes for any of the following defects. It is considered that these defects are undesirable in breeding stock and may be detrimental to the individual cats: ,

Folded Ears - Where the top of the ear is folded forwards instead of being pricked.

Skull - Any depressions or protrusions (The skull should be gently rounded to a greater or lesser degree according to the breed).

Entropion - Where the upper, lower or both eyelids turn inwards, allowing the lashes or hair to rub the surface of the eye.

Permanent Squint* - Permanent squint or any abnormality of alignment. Severe nystagmus - consult the Duty Vet.

Reduced Nostril Aperture - Narrowing of the nostrils vertically, horizontally or both, which may cause breathing difficulties It is often associated with flattened nasal bones and small nose leather.

Exaggerated Depression of the Nasal Bridge (stop) - The nasal cavity is severely reduced, which may cause breathing difficulties. This is often accompanied by blocked tear ducts. The nose should not be excessively short

Abnormal Position of Nose Leather - When the upper edge of the nose leather is above the lower edge of the eye.

Noticeably Undershot or Overshot Jaw

Narrow or Twisted Lower Jaw

Abnormal Angulation of Canine Teeth - When the mouth is closed the canine teeth should be nearly vertical, the lower canines fitting closely between the upper ones so that the anterior surface of the left upper canine and the posterior surface of the left lower canine almost touch, and similarly with the right upper and lower canines. The incisor teeth should form a straight line between the canines in both upper and lower jaws. The ideal bite is where the upper and lower incisors meet in alignment.

Deformity of Rib Cage

Fixed Deviation of the Sternum or Xiphisternum - The chest should be rounded or oval symmetrically from spine to breast bone when seen in cross-section. There should be no depressions or protrusions on spine or ribs. The sternum (breast bone) should follow a gentle convex curve with no deviation, depression or protrusion, and with no hook where the sternum ends.

Fixed Deviation (kink) of the Spine or Tail at any point* - Small bony excrescences need not debar the cat from being placed, but should be taken into consideration.

Luxating Patella in Adults - Where the kneecap can slip from the front of the joint towards the side.

Abnormal Number of Toes - Anything other than four toes on each foot and one dew-claw on each foreleg.

Hernia - Consult the Duty Vet.

Monorchid or Cryptorchid Adult Males - Both testicles must be descended and positioned in the scrotum in entire adult males.

*Squints and kinks have been included in the list because they are faults in all breeds, although they are unlikely to affect the health of the cat or its progeny.

This booklet provides explanatory notes for judges and breeders, but no list of defects can ever be complete. If any deviation from normal is suspected a veterinary surgeon should be consulted since other abnormalities may be seen occasionally.

EARS

Folded Ears

The ears vary in size and setting from breed to breed, but all are "pricked", as in the vast majority of non-pedigree cats. Folded ears are caused by a dominant gene, which in its homozygous form (i.e. received from both parents) can produce severe skeletal deformities in addition to the folded ear itself. In these cats the cartilage of the pinna (external part] of the ear is quite firmly folded forward.

Occasionally the tips of normal ears may bend slightly forward or back when a cat is teething or ill; the ear tips usually return to normal when the stressful period is over.

SKULL

The skull of all breeds should be rounded without pronounced protuberances or depressions. In short-headed breeds the curvatures from front to back and from side to side are almost equal, whereas in the long-headed breeds the curvature is more gentle from front to back than from side to side. In some breeds, particularly those with high set ears, the head may appear flat on top although the skull is in fact gently curved.

In all breeds the bony rims of the eye sockets can be felt at the front of the skull and there is a tendency for this to be more pronounced in short-headed cats. There is also a slight ridge at the back of the skull pointing towards the neck and there is a tendency for this to be more prominent in long-headed cats. However, none of these bony ridges should be so pronounced that they detract from the natural curvature of the skull.



In some cats the upper rims of the eye sockets are very pronounced, forming a "Neanderthal" ridge across the front of the skull, behind which there is a distinct depression before the skull rises again over the dome of the head. This can be detected by running a hand over the head of the cat from front to back with the ball of the thumb pressed gently against the skull; the ridge across the front will be felt, followed by a definite dip, running across the front of the head above the eyes, into which the thumb will sink to a greater or lesser degree before rising again over the dome.



A skull depression may alternatively take the form of a vertical indentation which produces a groove running from between the eyes upwards towards the dome of the skull. Some cats have a noticeable indentation above the nose, without a continuation of the depression either vertically or horizontally.



In many short headed cats the top of the head is also deformed, with a very pronounced central dome or several bumps and dips instead of a smooth curve. In some long-headed cats the front of the skull protrudes centrally, producing a bony protuberance above and between the eyes.



The very slight skull depressions seen in some kittens may disappear when the skull achieves its adult shape, but skull protuberances in kittens often become more pronounced with age.

EYES

Entropion

In a normal cat the hair of the face, eyelids or eyelashes should never rub against the surface of the eye; a narrow strip of hairless skin should be visible at the edges of the upper and lower lids, in the condition known as entropion the upper, lower or both eyelids are deformed so that they tend to roll inwards towards the eye, allowing the hair or lashes to rub against the eye itself. This is often more noticeable when the

eyes are closing and the rolling can be observed. This, obviously, causes irritation to the surface of the eye and is most uncomfortable for the cat.

Abnormality of eye alignment

A squint may occur in one or both eyes; the eyeball does not have its normal range of movement, so that the eye appears to look in the same direction permanently, usually towards the nose. Many cats will have a slight squint when under stress: this is not permanent but may appear so at a show if the cat remains tense all day.

Although a squint is unlikely to affect the health of a cat or its offspring it may impair vision and does detract from the appearance of the cat. As it was already detailed as a fault in many breeds and was considered undesirable in all breeds it has been placed in the general list of defects.

In some long-headed cats, especially those with protuberant bone between the eyes, the eyes are very deep-set. The third eyelid (haw) is often very prominent and it may be impossible to tell if a squint is present (and difficult to see the eye colour). These cats may also suffer from entropion.



In some short-headed cats the eyes are positioned abnormally far apart and show an outward cast, with one pupil facing outward when the other pupil looks forward. These cats often show an abnormal amount of the white of the eye.

Nystagmus


In this condition the eyes flick or roll from side to side, often becoming worse if the cat is stressed. It may be seen in cats which are brain damaged for a variety of reasons, but can also be seen in otherwise normal cats, especially those with Siamese/Colourpointed coat pattern in which occasionally a high frequency oscillatory type of nystagmus occurs that is thought to have a genetic basis. A veterinary surgeon should always be consulted in cases of abnormal eye movement. Some types of nystagmus may warrant veterinary rejection on humane grounds especially if other signs of brain disease are present.

NOSE

It may seem rather obvious to state that a cat should be able to breathe through its nose but, regrettably, some cats find this very difficult. The nose contains a labyrinth of fine bones (the turbinate bones) covered in mucous membranes which warm the air before it reaches the lungs and remove debris and some infectious agents. If this function of the nose is impaired the cat's health will suffer,

If the cavity of the nose is reduced, not only is the function of the nose itself impaired, but the cat may actually find it difficult to breathe through the nose and have to resort to mouth-breathing, especially when stressed.

In addition, tears drain from the eye into the nose through fine ducts. When the nose is deformed these ducts are often narrowed or completely blocked, causing the tears to drain down the front of the face instead. Not only is this unsightly, but the permanent dampness encourages infection and may also cause a dermatitis.



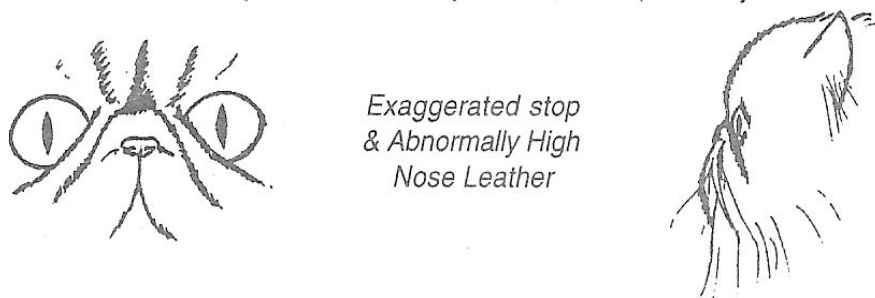
Reduced Nostril Aperture

Normal nostrils allow free passage of air to and from the nose. If their apertures are reduced breathing becomes more difficult. Unfortunately, flattened nostrils are often seen in cats which also have reduced nasal cavities, adding further to their breathing problems.

Narrow nostrils are easy to detect if looked for. They may look as though they have been "pinched" from side to side, or from top to bottom. The nose leather itself often has this same "pinched" look, or may be reduced by the extension of hair-bearing skin down to nostril level. In some cats the nose leather is a tiny square instead of an ample triangle.

**Exaggerated Depression of the Nasal Bridge (Stop)
Abnormal position of Nose Leather**

Even in the breeds with the shortest heads the standards of points call for a short nose, a short broad nose or a snub nose, not for the absence of a nose. Unfortunately, in the attempt to produce flatter and flatter faces, the noses in some cats have been shortened almost to nonexistence. Instead of a short, neat nose it is as if the nose had been squashed into the face, causing a depression between the eyes and placing the nose leather, often reduced in area, just below this depression, between the eyes.



A side effect of this is that, in many cases, the skin of the face itself forms folds below the eyes, detracting from the pleasing roundness of the eyes and increasing the likelihood of eye problems and dermatitis.

The selection for a nose placed between the eyes in a flat face also affects the position of the eyes (q.v.), moving them outwards in the skull. The combination of large bold eyes placed wide apart in a very flat face predisposes the eyes to injury.

JAW

Jaw problems may occur, and are a withholding fault, in any breed. By lifting the cat's upper lips gently, whilst keeping its mouth closed by supporting the chin, and looking at it from the front and side it is easy to detect jaw faults. If the mouth is actually opened the faults may be missed. Care must be taken not to

angle the cat's head abnormally when checking the bite, since this may make the bite appear abnormal when it is not. Teething kittens may also appear to have irregular bites.

In a normal cat the mouth should be able to close completely, allowing the cheek teeth to shear neatly past one another. When the mouth is closed the canine teeth should be nearly vertical, the lower canines fitting closely between the upper ones so that the front of the upper canine and the back of the lower canine almost touch each other. The canine teeth should not protrude so that they rub on either the upper or lower lips. In older cats it is quite common for the upper canine teeth to be more prominent (literally "long in the tooth") but they should still be correctly aligned and cause no discomfort.

The six incisors in each jaw should run in straight lines between the canine teeth and when the mouth is closed they should meet. This is known as a level bite.

Undershot or Overshot Jaw

When the lower jaw protrudes in advance of the upper one it is commonly known as "undershot". When the reverse occurs and the upper jaw protrudes it is commonly known as "overshot". Both are faults in any breed. Most breeds of cat are required by their standards to have firm chins but this can be achieved in a cat with a perfect level bite, as can be seen by examining non-pedigree cats and the more moderate type breeds.

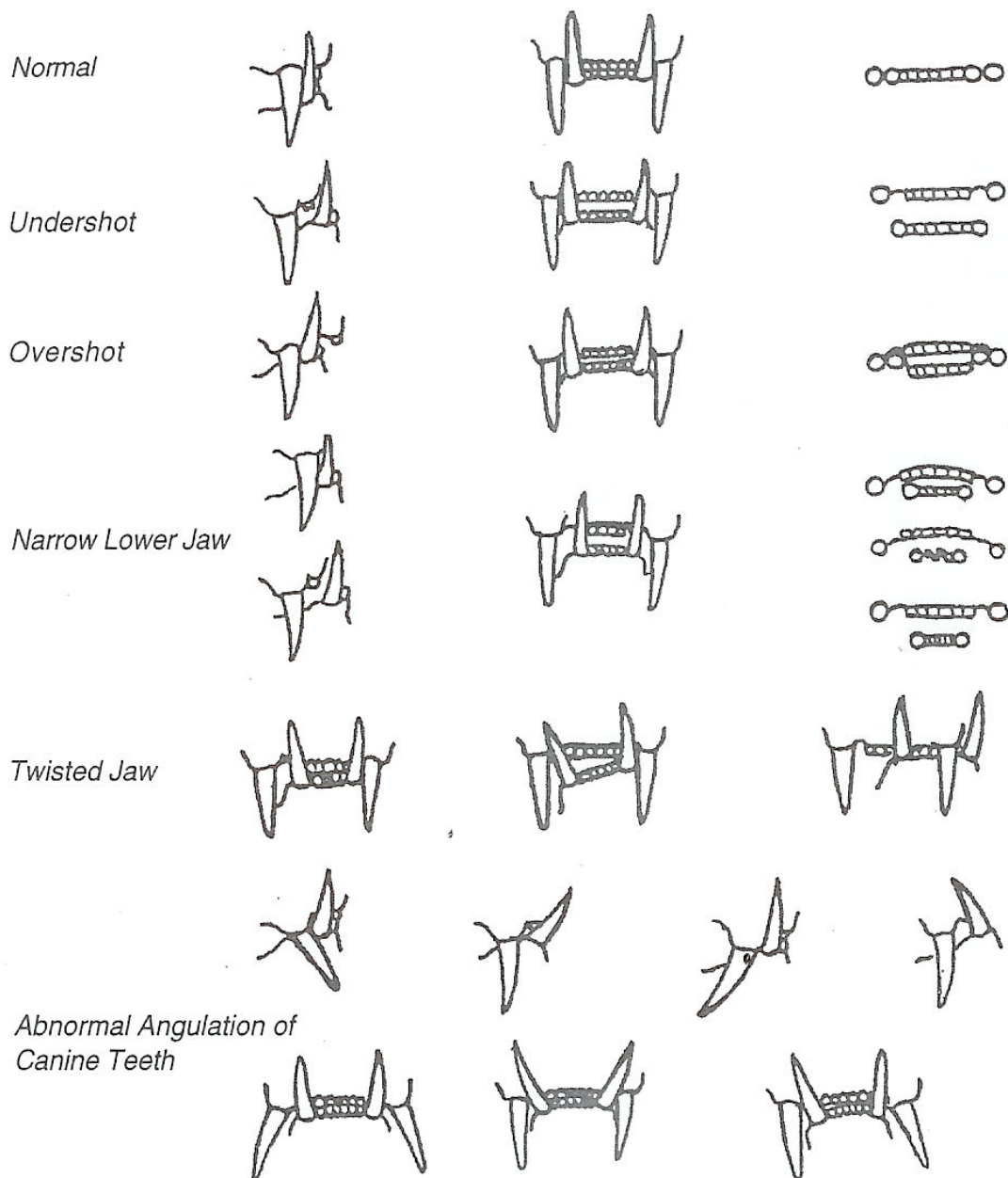
Some Persian and Exotic kittens may be very overshot; the gap between upper and lower incisors can be very marked - 50mm or more - so that the lower canines dig into the hard palate causing pain and difficulty with feeding. Despite the fact that the bite may become perfectly level as the kitten matures, this degree of discomfort cannot be considered acceptable.

Narrow Lower Jaw

Instead of the lower canine teeth fitting neatly between the upper ones they are placed too close together leaving a noticeable gap on either side. There is usually too little space for six incisors to lie in a straight line between the canines and either they are misaligned or some may be missing. In a cat with a level or overshot mouth it can cause severe problems as it can be difficult for it to close its mouth completely. In some of these cases the upper, lower or all four canine teeth, instead of being nearly vertical, point forwards or sideways, sometimes almost horizontally.

Twisted Lower Jaw

The lower jaw, instead of being set straight, as in the ideal mouth described above, may be twisted to one side or may even be rotated so that one canine is higher than the other. When a twisted lower jaw is also narrowed the lower canine teeth usually lie between the upper pair, but when viewed from the front it can easily be seen that the gap between the upper and lower canines is greater on one side than on the other. When assessing this it is important to try and get the cat to relax as it is possible for a cat to hold the lower jaw to one side due to muscle tension. Sometimes just letting the cat open its mouth and close it naturally will make it release the tension and the jaw will close normally.



When the lower jaw is of more normal width the twist may bring one of the lower canines to lie outside the upper canine and this is impossible to miss. There is sometimes so much distortion that the lower canine can be seen protruding outside the upper lip.

In some cats the whole jaw and nose may show a deviation to one side.

Abnormal Angulation of Canine Teeth

Sometimes, instead of being set nearly vertically, the upper or lower canine teeth may incline forwards, sideways or occasionally backwards. This, again, can be detected easily by looking at the teeth from front and side.

An abnormality occasionally seen in Siamese and Oriental breeds is an absence of normal permanent canine teeth. The temporary (milk) teeth are usually themselves abnormal, which may not be noticed, but when they are lost they are either not replaced at all or are replaced by fine spikes, smaller than temporary canines and often pointing forwards.

Other jaw abnormalities

In some cats the upper incisors, instead of forming a straight line, curve backwards creating a jaw which is undershot centrally although level at the sides. This is most often seen when the upper jaw is narrowed.

Some cats have malocclusion of the cheek teeth resulting in a mouth which cannot close although the canines and incisors appear normal. The tongue often protrudes. (This effect can also be produced in older cats by excess tartar or loose teeth preventing normal closing!)

Kittens

Most jaw deformities are more noticeable in an adult jaw, but careful examination of a kitten will reveal them. What may start as a minor deviation in a kitten will usually be magnified by the time it is an adult. A slightly undershot jaw in a short-headed kitten will generally become more undershot as the kitten grows. Similarly an overshot jaw in a long-headed kitten is unlikely to correct as the kitten gets older. A twisted lower jaw can be detected at a very early age, virtually as soon as the canine teeth erupt. In such a tiny jaw there may be only a fractional difference-between the canine gaps, but this will usually be observed to increase as the jaw develops. A twist to the nose and jaw may sometimes be detected at an early age although it may be very slight.

BODY

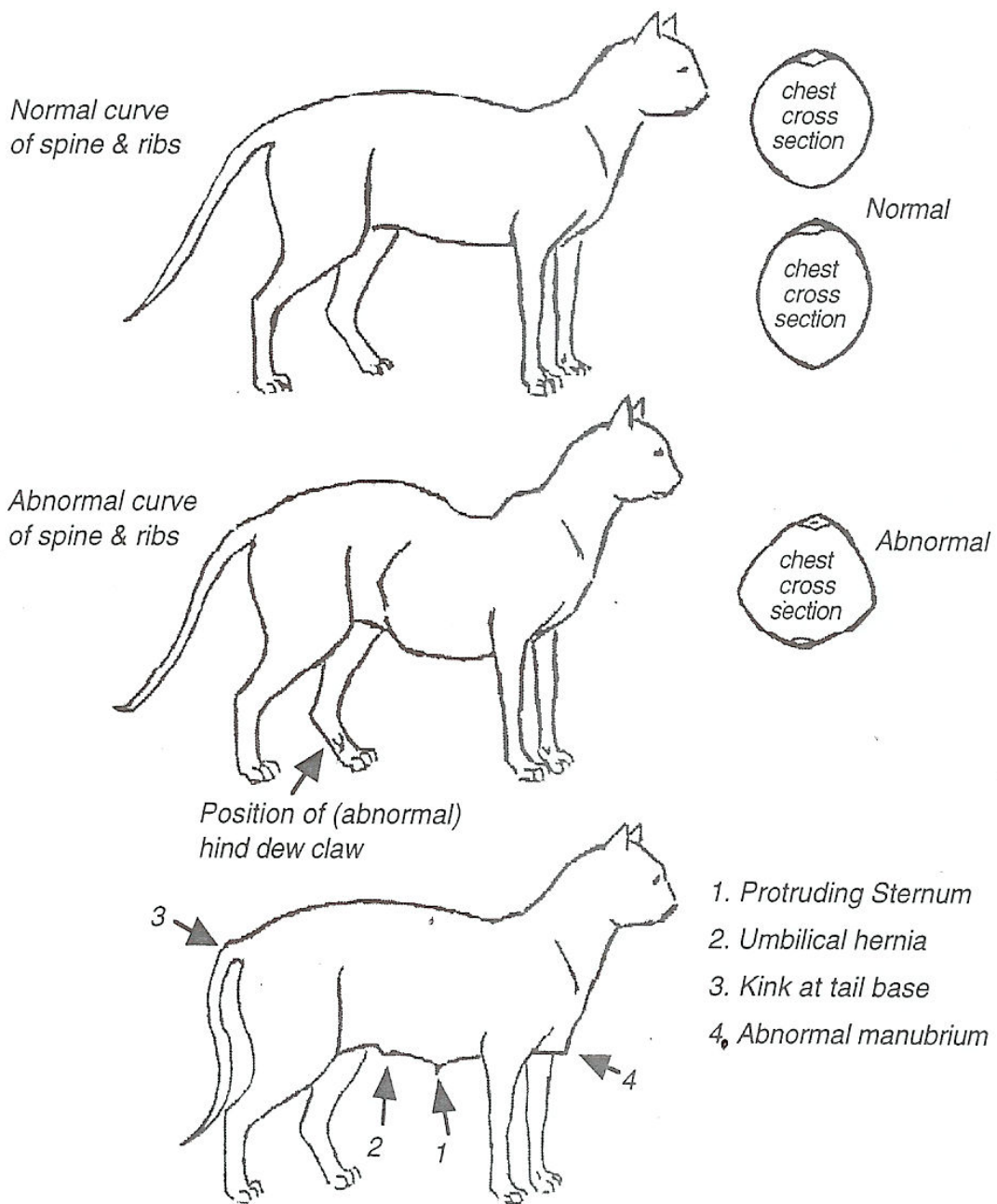
In a short-haired cat deformities of the body are usually quite obvious, but in a long-haired cat they may not be visible. Deformities of the body can be felt by running a hand along the cat from the top of the head to the tip of the tail, running the hands along the sides of the body and down the sides from the spine, then running a hand along the underside of the cat from the front to the rear.

The entire cat should be felt, gently but firmly, not only to check for defects but to establish that there is normal muscle tone for the age of the cat and normal weight for size,

Deformity of the Rib Cage

The spine may deviate sideways at any point or may have an overpronounced dip behind the shoulders, often followed by a sharp rise. Any deviation from the normal is a defect. Some cats when tense will appear to be hunch-backed; if persuaded to relax the spine will return to normal.

The shape of the rib cage itself is more rounded in cross section in a cobby cat and more oval in a foreign type cat, but should never be angular. Sometimes angulation can be felt when running the hands down the sides from the spine and this is often an expression of flat-chestedness. One or more ribs may be affected on one side only and care is necessary to detect these as they are easily missed- Sometimes the ribs can be felt to flare out at the rear end of the chest and this is also a deformity.



Fixed Deviation of the Sternum or Xiphisternum

The xiphisternum is the rear end of the sternum (breastbone). When a hand is run along the underside of the cat from between the front legs backwards there should be a very gentle curve outwards under the chest, running almost unnoticeably into the softer contour of the abdomen, with no protrusion or dip at the rear end of the sternum. There should be no bumps, dips or sideways deviations of the sternum itself.

Sometimes a distinct hook or a noticeable outward curve may be felt at the rear end of the sternum, but sometimes there is an indentation where the end of the sternum bends inwards. All are defects.

The xiphoid cartilage at the end of the sternum varies in size and is longer in some **cats** than in others, but provided it continues the line of the sternum this is not abnormal.

Sometimes, especially in kittens, the end of the sternum is flexible. This is usually the xiphoid cartilage which can be felt. In a fat cat or one which has a full stomach this flexible end may protrude slightly but can usually be pushed into its normal position by very gentle pressure. This will usually be a perfectly normal sternum when the xiphisternum hardens. However, sometimes, although the end is flexible, even when it is straightened as far as possible by gentle pressure there is still a deviation from the normal shape. This is a defect.

The front end of the sternum (manubrium) may sometimes be rather prominent. This is usually more noticeable in kittens or in cats which have not yet muscled up and is not in itself a defect. However, in some cats, the front end of the sternum may be abnormally wide, flattened, concave, **or** even come to a pronounced point, none of which are normal.

Fixed Deviation (Kink) of the Spine or Tail at Any Point

When a hand is run along the spine the tail should be felt to continue the line of the spine, with no deviation. Although many kinks are at or near the tip of the tail they can also occur at any point along the spine or tail or even right at the base of the tail where it leaves the body. The spine should be checked and the tail itself should be felt, very gently, from various angles. If the tail is only felt with thumb above and fingers below it is easy to miss a kink which deviates sideways- Similarly, an upwards or downwards deviation may be missed if the tail is only felt from side to side. The examination should be deft but brief and gentle; finger nails should not be pressed into or between the bones of the tail and the tail tip should never be "twiddled" since this can cause soreness.

Sometimes a cat will hold the end of its tail at a slight angle but if the tail is perfectly normal when it is examined this is not a defect. Other tails may be felt to have an abnormally blunt or inflexible end or very slight hard or soft swellings without any deviation and although these do not debar the cat from being placed they should be taken into consideration when judging the cat.

Although a kink in the tail rarely affects the cat in any way, similar kinks in the spine can have more serious consequences.

Hernia

When a hand is run along the underside of a cat a soft swelling may be felt in the midline of the abdomen, behind the end of the sternum. This usually indicates an umbilical hernia. Sometimes this swelling disappears with gentle pressure on it but the rim of the hernia can usually still be felt. An inguinal hernia can sometimes be detected in the groin region, but can easily be confused with inguinal fat. If a hernia is suspected a veterinary surgeon should be consulted to confirm its presence or absence.

LIMBS

Luxating Patella in Adults

The patella (kneecap) should lie on the front of the knee joint on the hind leg, moving slightly up and down as the joint bends and straightens. In kittens it is often possible to move the kneecap slightly from the front of the knee joint towards the side, usually the inside, of the joint by gentle pressure. In an adult cat only very slight movement should be possible and it should not be possible to move the patella out of the groove in which it sits, except by force. Sometimes a click will be felt when the knee joint is bent or straightened and this can indicate a luxating patella. If this is suspected a veterinary surgeon should be consulted.

Abnormal Number of Toes

True polydactyly is caused by a dominant gene so it is very rare in pedigree cats. However a less common, and unconnected, condition may be seen in pedigree as well as non-pedigree cats: in these cats there is a dew-claw on the hind legs similar to that on each front leg but often placed midway between foot and hock. This can easily be missed, especially in a long-haired cat, unless the legs and feet are examined carefully.

Other bone deformities

Other bone deformities such as bowed legs, thickened joints or thickened vertebrae may sometimes be detected. If an abnormality is suspected a veterinary surgeon should be consulted to confirm its presence or absence. Some such abnormalities may be due to injury.

MONORCHID AND CRYPTORCHID ADULT MALES

Any entire adult male cat (nine calendar months of age or more) which does not have both testicles fully descended into the scrotum must be disqualified from competition and should indeed be rejected at vetting-in. In some breeds, lack of two normal scrotal testicles in un-neutered male kittens is a withholding fault.

Although kittens are not rejected or disqualified for this fault they should not be selected as future studs. In many cases, if the testicles are not positioned within the scrotum by three months of age they will not descend at all. In some cases they will descend later but these kittens should still be viewed as dubious prospects as future studs since late descent is almost certainly a minor expression of the same defect. Some of these abnormal cats may have testes which lie just anterior to the scrotum but can be manipulated to lie within the scrotum for a short period.

Although a male with no descended testicles is usually sterile, if one testicle is descended the cat is capable of siring but should not be used as a stud. A retained testicle is more likely to develop cancer than a descended testicle so the cat should be neutered. However, as the retained testicle may be positioned anywhere between the inguinal canal and the kidney, this operation is frequently more complicated than spaying a female cat. For this reason it is highly desirable to try to avoid producing kittens with this abnormality. A Certificate of Entirety is now required for any stud before his progeny may be registered.

CORRECTION OF DEFECTS IS A BREACH OF GCCF RULES

Some of the defects described above can affect the health or comfort of the cat and therefore require correction. This includes such defects as entropion, hernias, severe luxating patellas and some dental abnormalities. Cats which have had such corrective surgery must not be shown. Even if a defect is corrected in the course of performing some other operation, the cat still must not be shown.

The GCCF Rules state, in the declaration to be signed on show entry forms (Section 4, Rule 3e) "To the best of my knowledge the cat(s) entered for this show has/have not been subjected to any surgery to correct any defect listed in the GCCF standard of points."

Any breach of this rule could render the exhibitor liable to disciplinary action by the GCCF.

Any operation which corrects a defect is a breach of this rule. This includes the extraction and/or alteration of abnormally angled teeth. Whether the angulation was "natural" or appeared to be due to an accident, if the tooth was fixed in an abnormal position and is then extracted or altered it is a breach of the rule.

The correction of any anatomical abnormalities, whether or not they are included in the "List of Defects", might be construed to be a breach of Article 12 (1) (b) of the GCCF Constitution if the cat was subsequently shown or sold for showing or breeding.

The only "exception" to this rule is the neutering of a monorchid or cryptorchid male. Here the defect has not been corrected but totally removed and the neutered cat may be shown.

ELIMINATION OF DEFECTS

As the desire of any concerned breeder must be to try to eliminate any defects which can affect the health or comfort of cats, it is obviously undesirable to breed from any cats with defects, and especially from those displaying severe examples of any defects.

This is, however, a counsel of perfection: certain defects are so widespread in some breeds that it is virtually impossible to avoid breeding from cats showing some degree of defect without destroying the breed itself. Only careful selection over many generations will eliminate the prevalent defects completely from these breeds. However, care must be taken that cats showing defects less common in that breed are not bred from.

In other breeds the listed defects are far less common and great care should be taken to avoid breeding from any cat displaying any defect, lest they become more common. Even cats which, although normal themselves, produce kittens displaying defects should be viewed with suspicion.

The fact that it may be necessary to breed from a cat showing a minor expression of a defect does not mean that the cat should be shown and be expected to win. Judges too should help to eliminate defects by penalising them on the show bench wherever they are encountered.

11.6.03